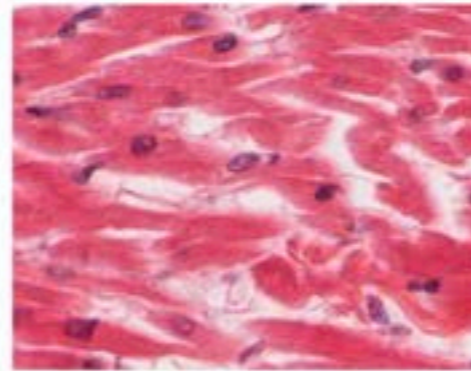


**Nervous tissue**

- Brain
- Spinal cord
- Nerves

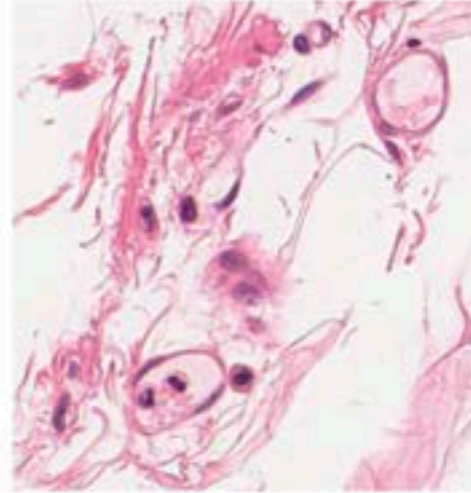
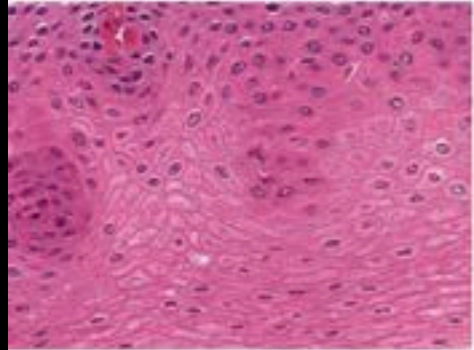


**Muscle tissue**

- Cardiac muscle
- Smooth muscle
- Skeletal muscle

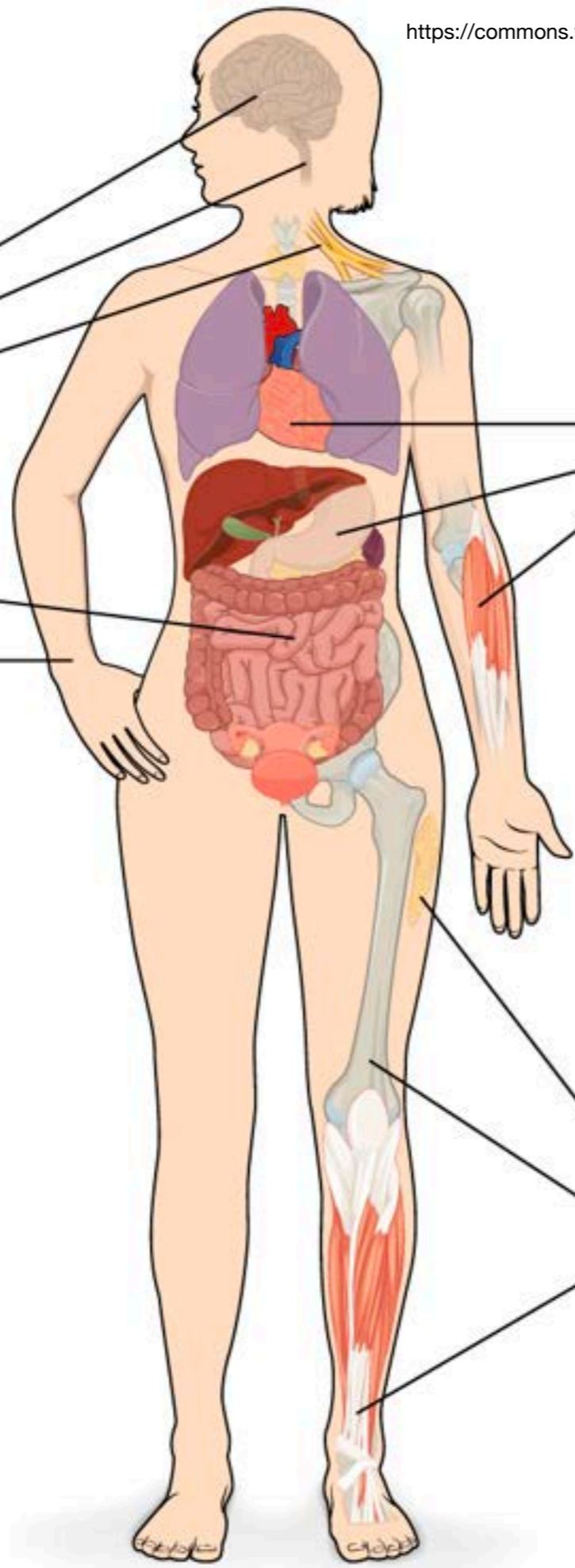
**Epithelial tissue**

- Lining of GI tract organs and other hollow organs
- Skin surface (epidermis)



**Connective tissue**

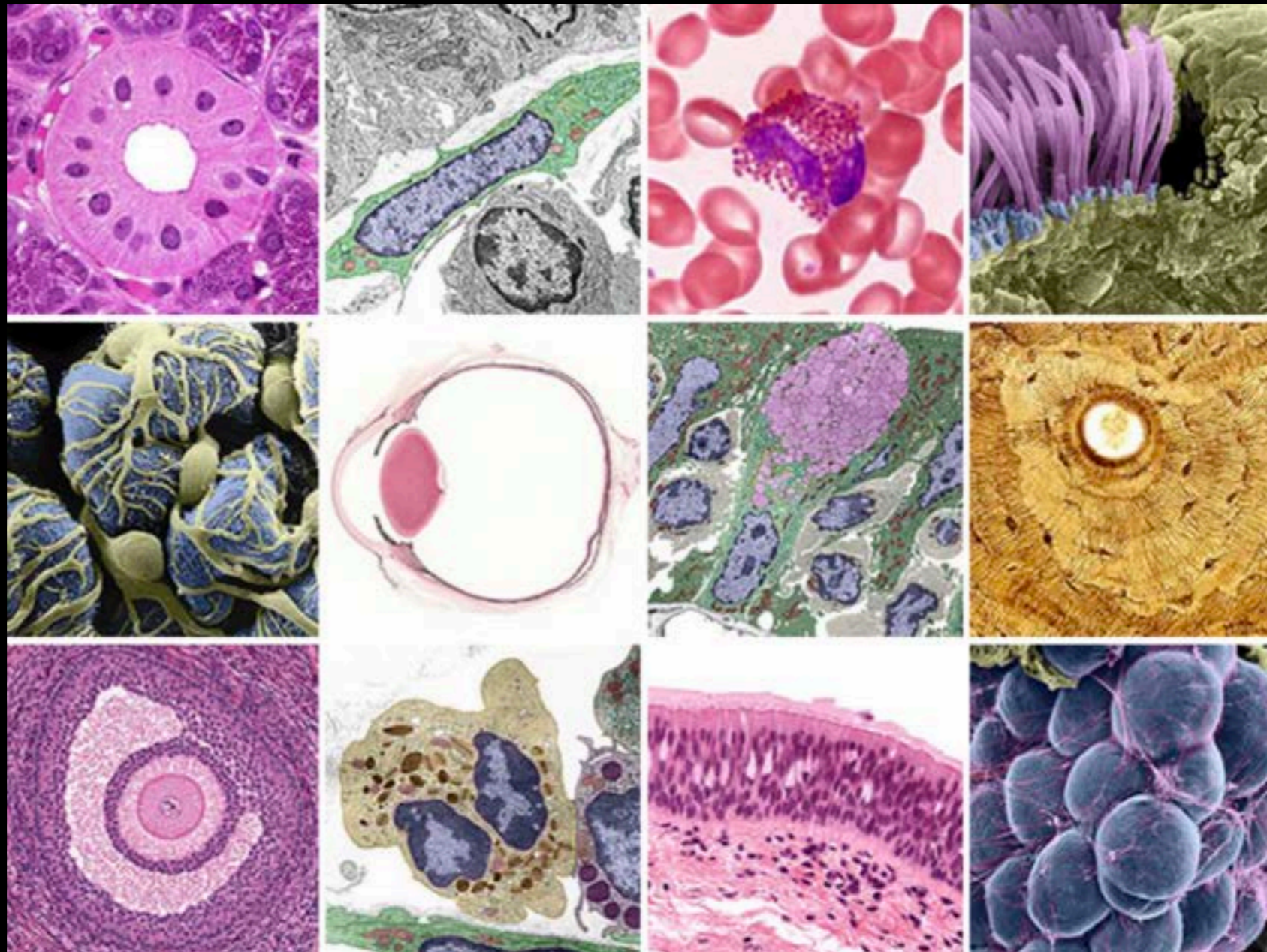
- Fat and other soft padding tissue
- Bone
- Tendon



# Tessuti del corpo umano

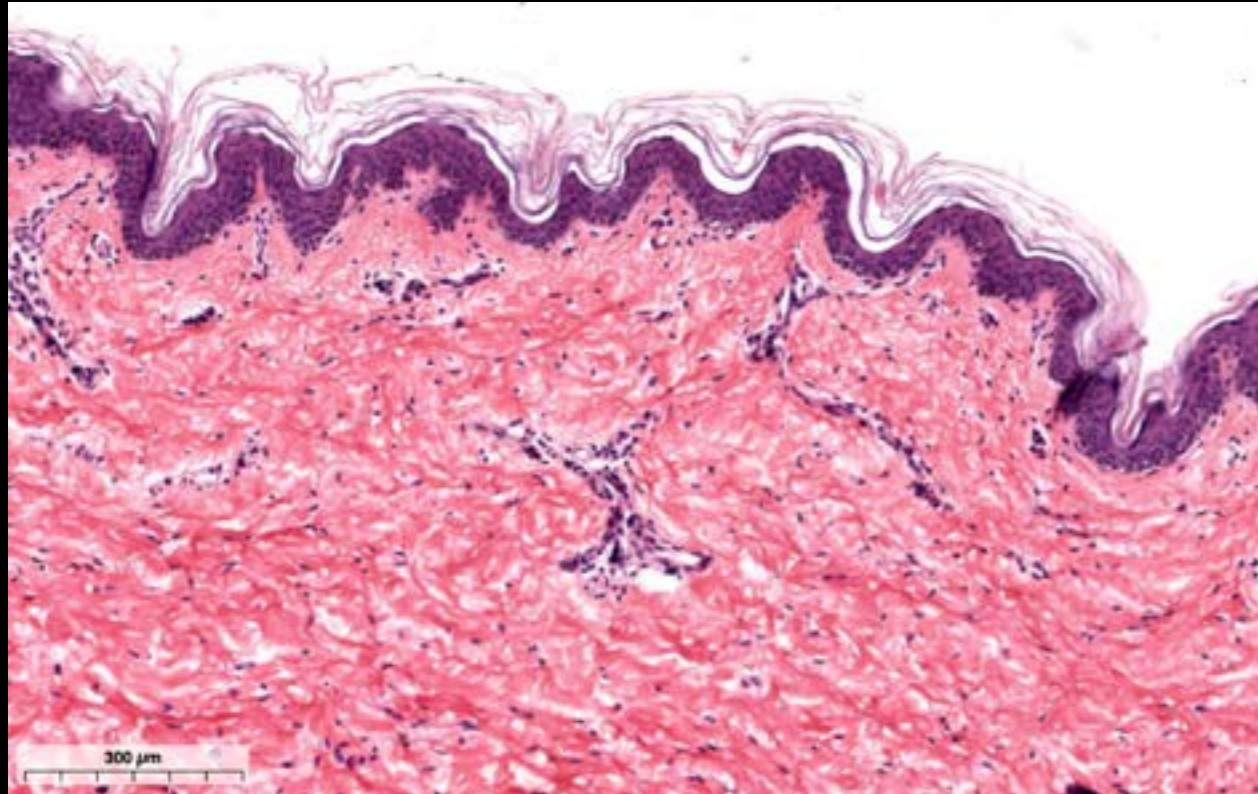
Fonte delle immagini

# Histology Guide - Virtual Microscopy Laboratory

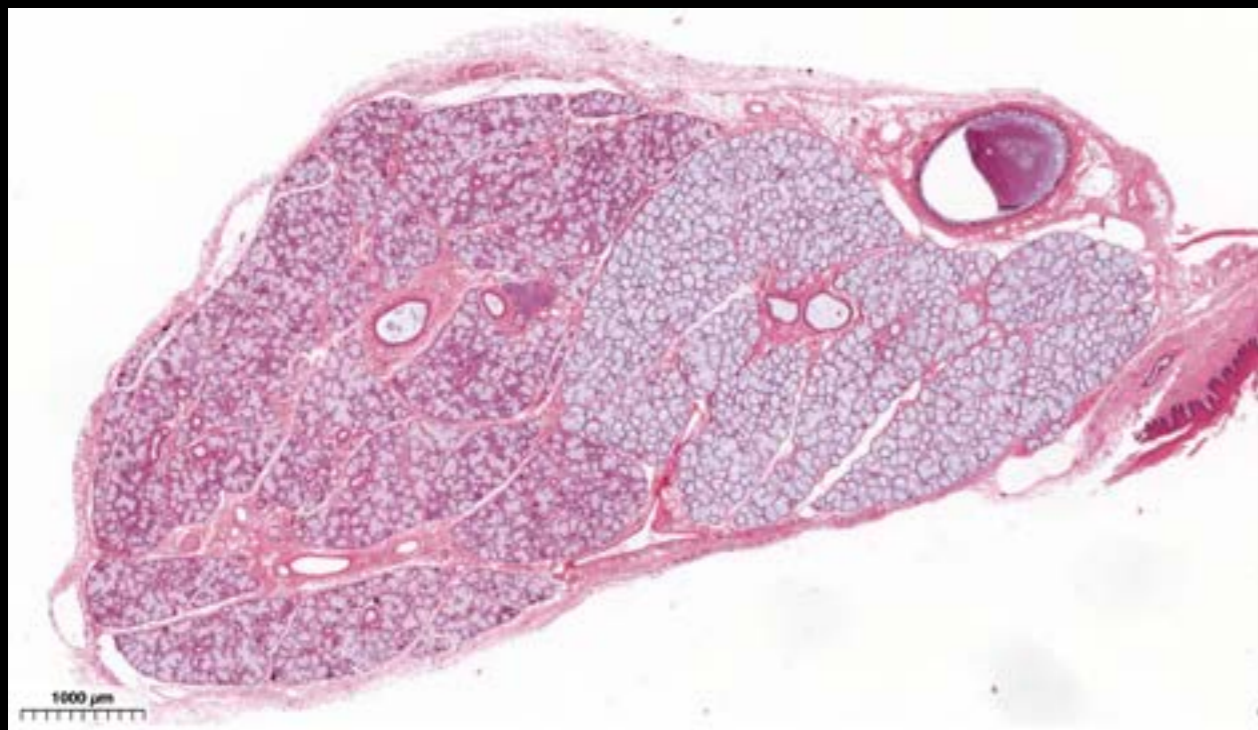


# Tessuto Epiteliale

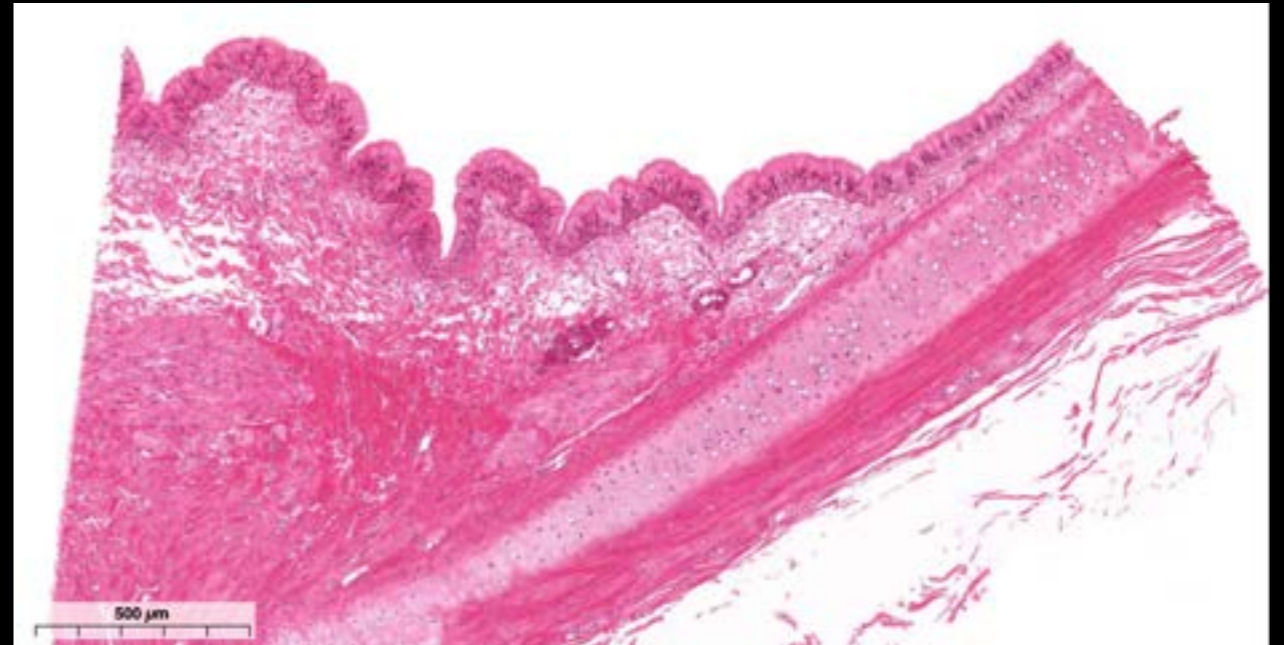
Epitelio stratificato squamoso cheratinizzato - Pelle



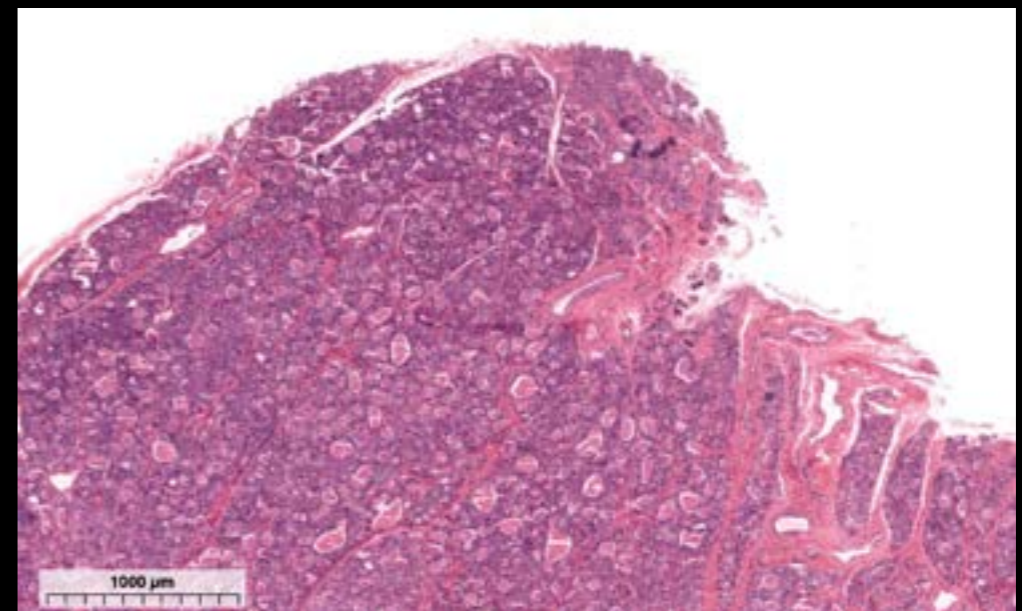
Ghiandola sottomlinguale - Ghiandola salivare



Epitelio colonnare pseudostratificato - Trachea



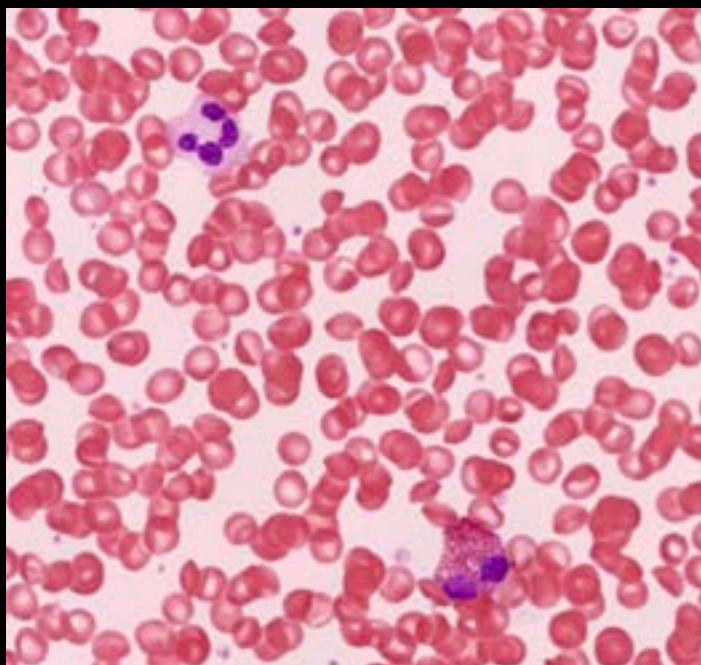
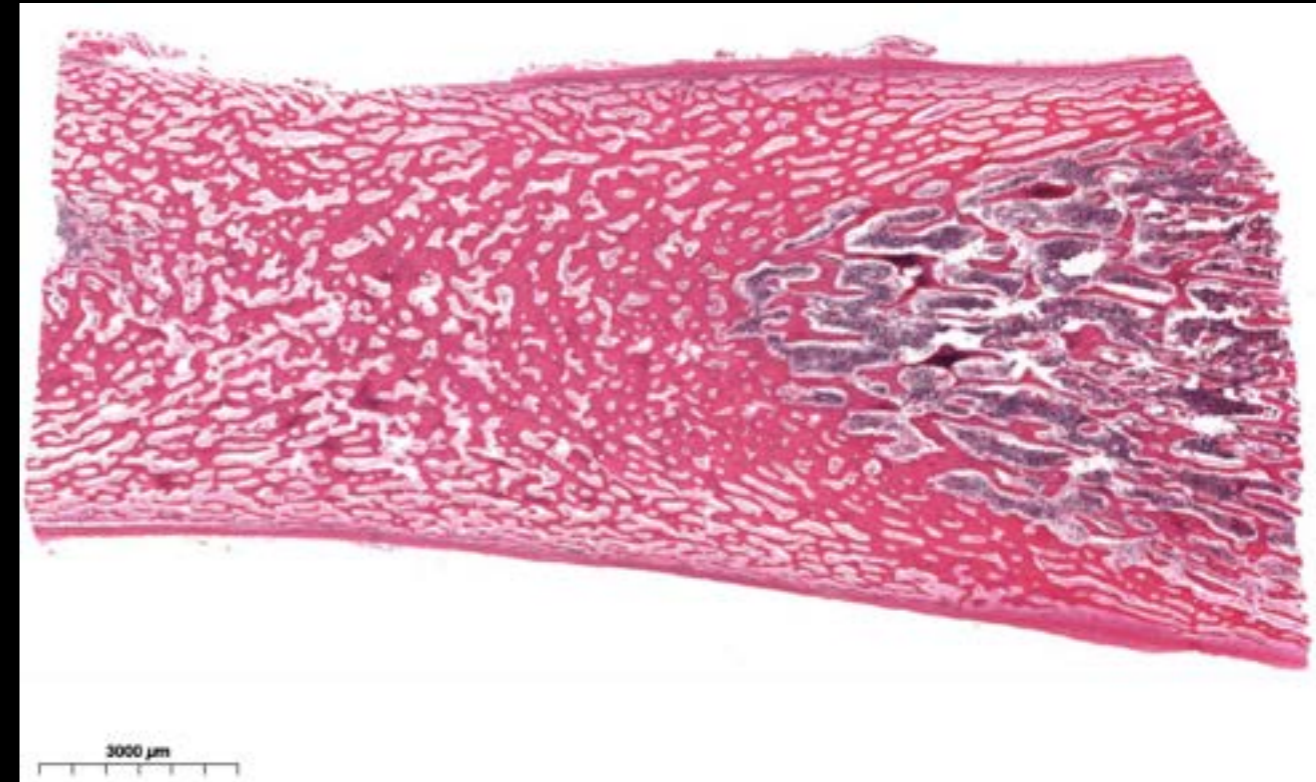

Tiroide



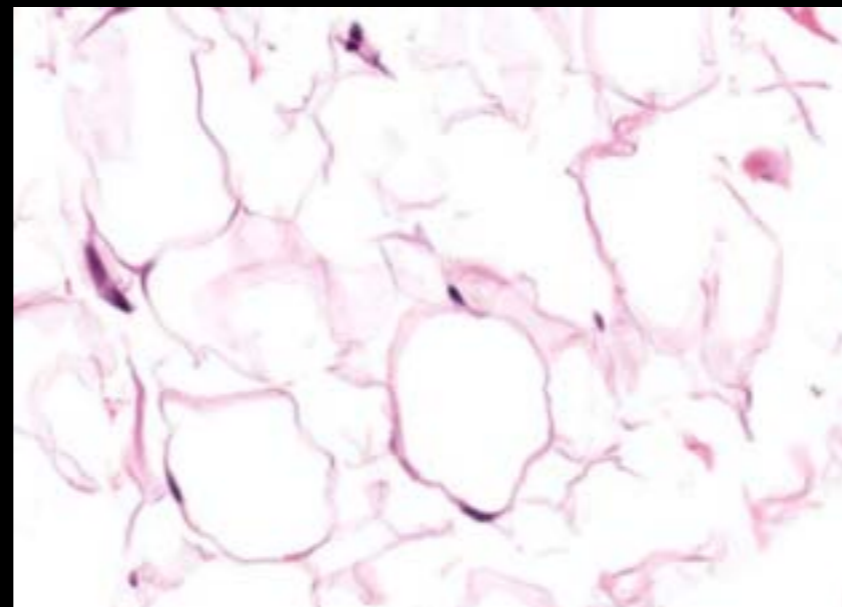
# Tessuto Connettivo

Connettivo denso - Collagene - Tendine

Ossificazione endocondrale - Osso



Sangue



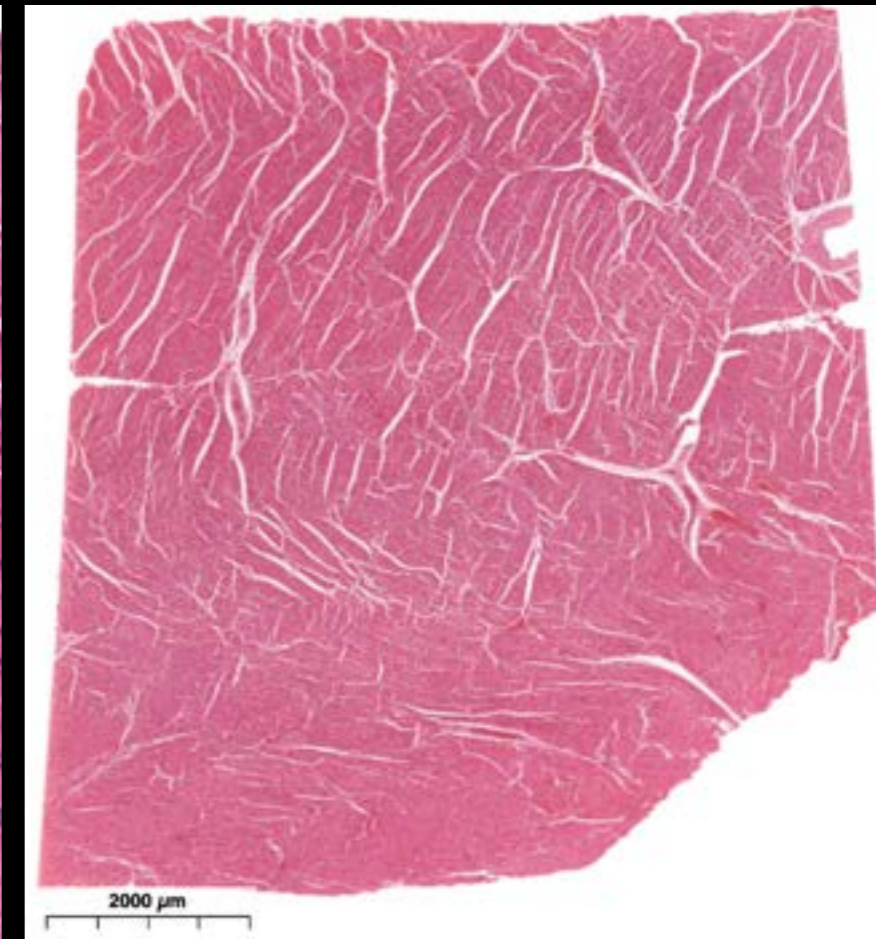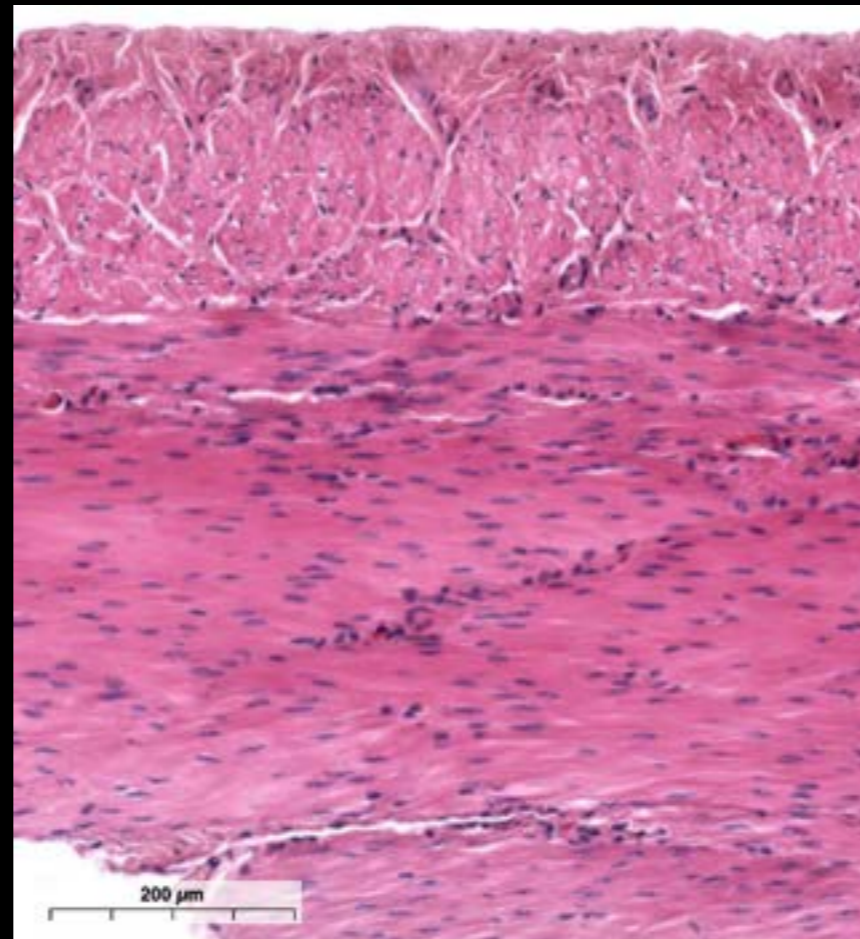
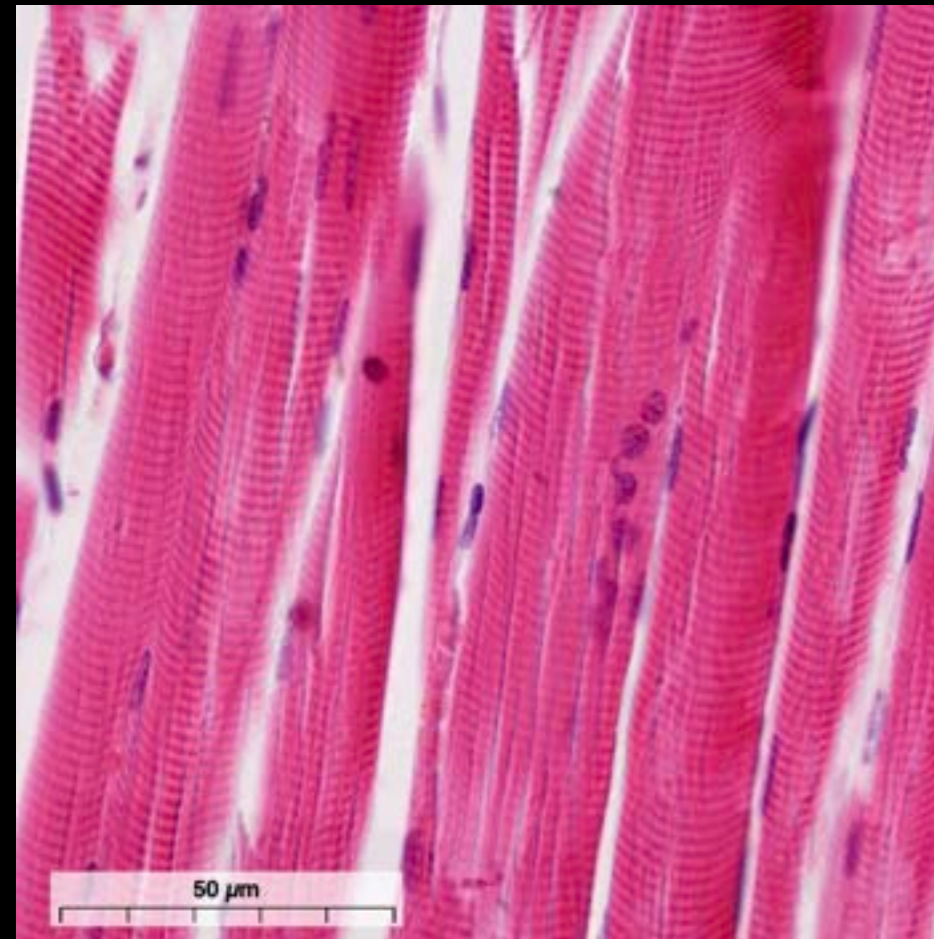
Tessuto adiposo

# Tessuto Muscolare

Muscolo scheletrico

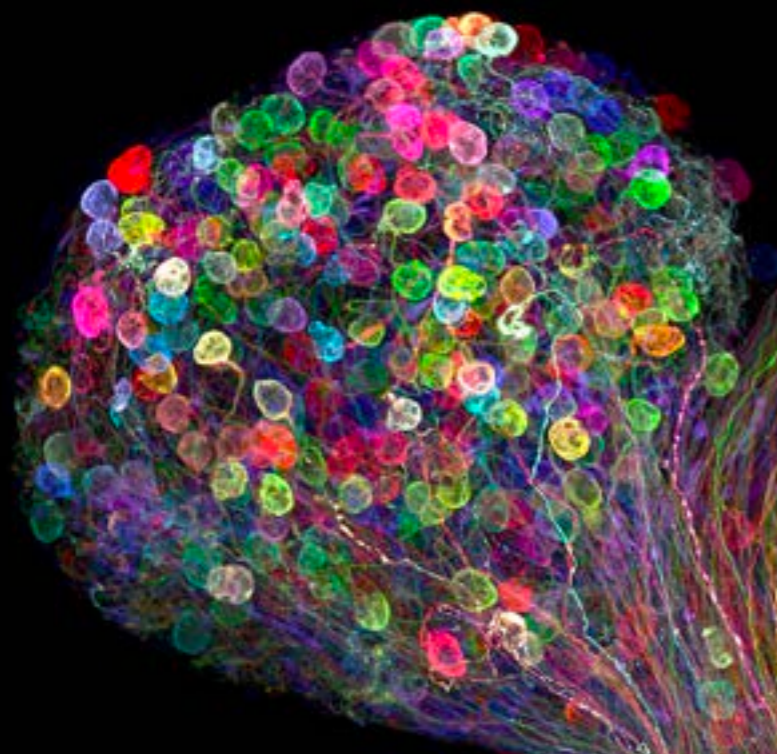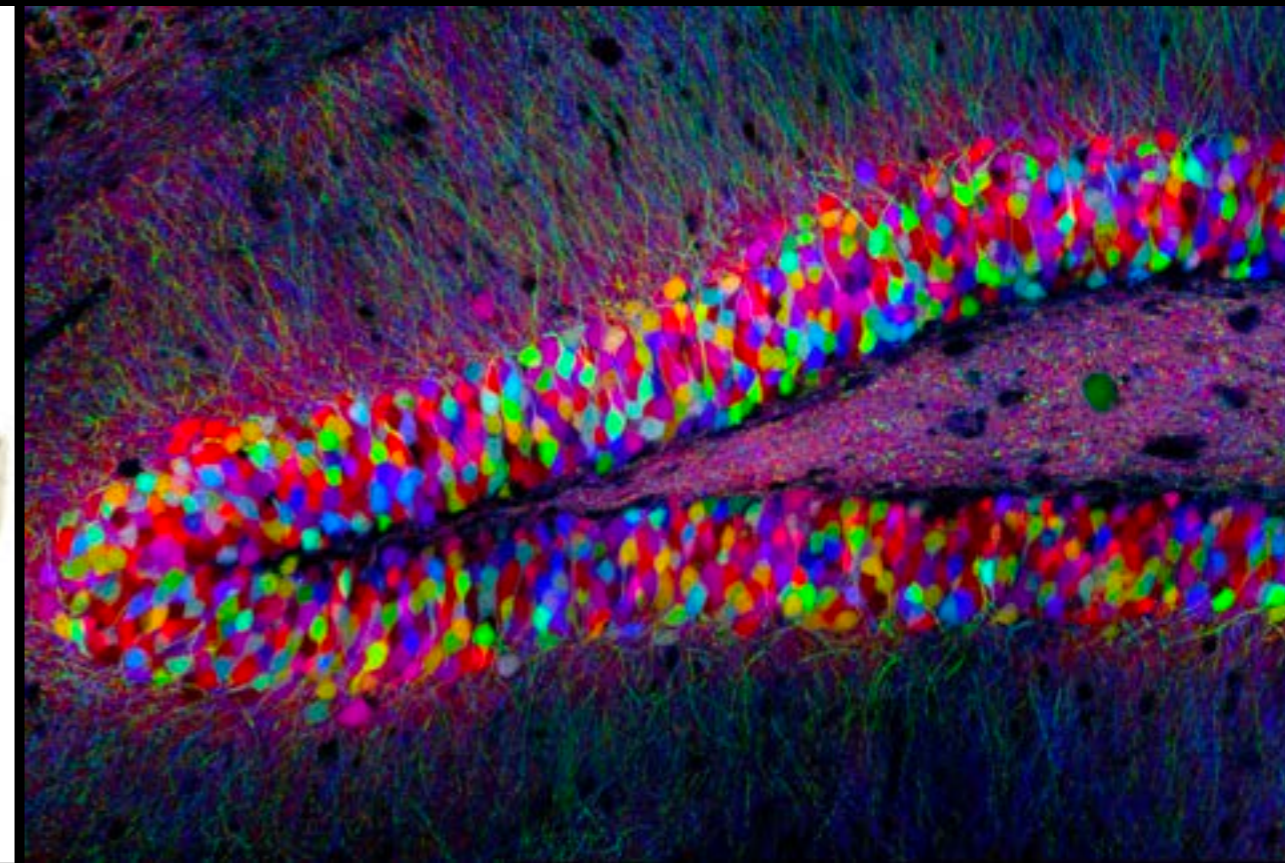
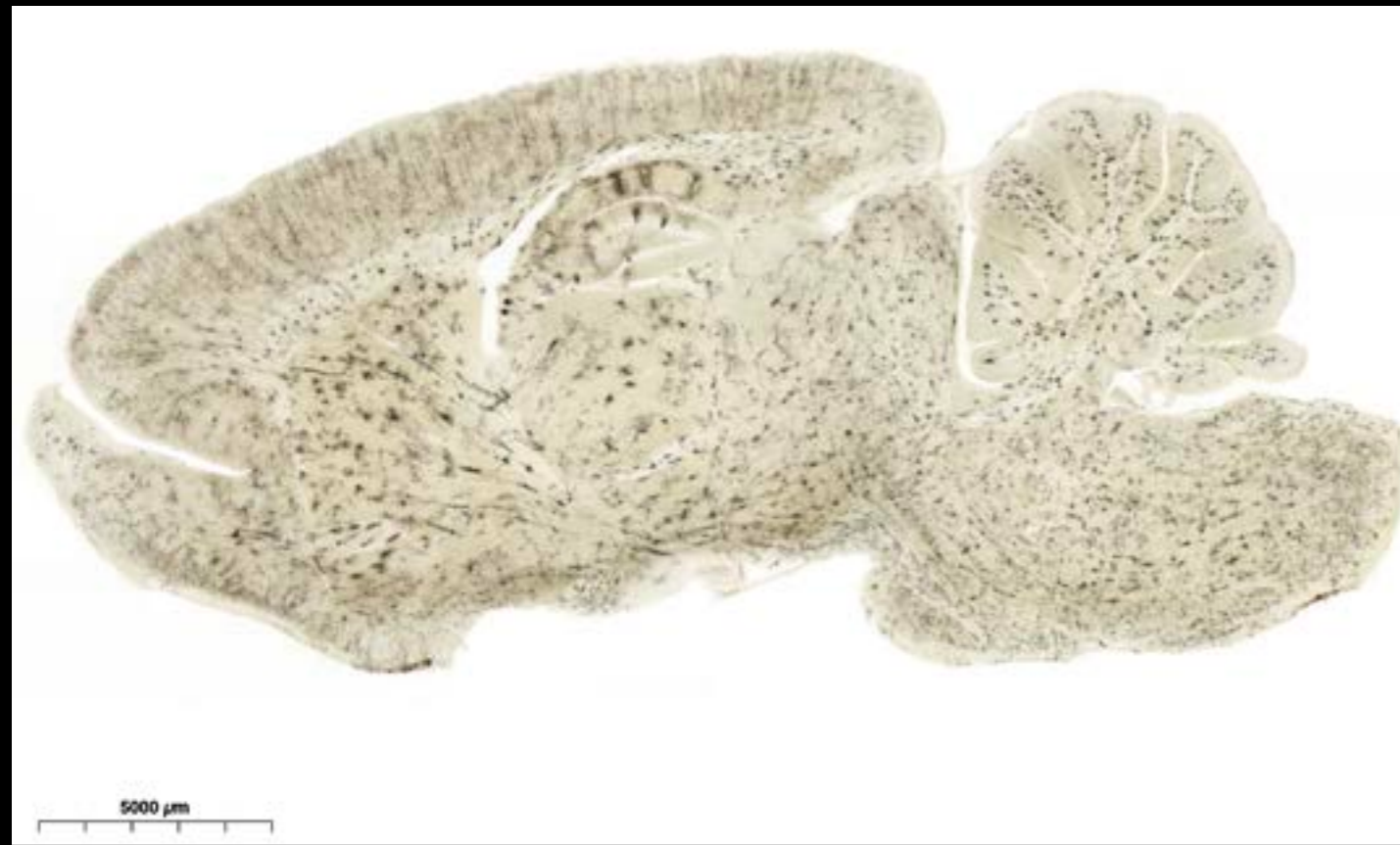Muscolo liscio

Muscolo cardiaco



# Tessuto Nervoso

Cervello



“Brainbow” transgenic mouse hippocampus  
Image Source (Nikon Small World)

<https://www.nikonsmallworld.com/galleries/2008-photomicrography-competition/brainbow-transgenic-mouse-hippocampus>

Individually labeled axons in an embryonic chick ciliary ganglion  
Image Source (Nikon Small World)

<https://www.nikonsmallworld.com/galleries/2017-photomicrography-competition/individually-labeled-axons-in-an-embryonic-chick-ciliary-ganglion>